

Initial Clinical Experience with a Novel Dual Blade Device: Safety and Utility of Use

Jeffrey B. Kennedy, MD, Jeffrey R. Soohoo, MD,
Leonard K. Seibold, MD, Malik Y. Kahook, MD

PURPOSE/ RELEVANCE

- The main obstruction to aqueous outflow in glaucoma is the trabecular meshwork, with a corresponding increase in intraocular pressure (IOP)
- Recently, several techniques have been described for performing ab-interno trabeculotomy and trabeculectomy in an attempt to lower IOP.¹⁻⁴
- This study aims to assess the safety and efficacy of the Kahook Dual Blade (KDB, New World Medical, Rancho Cucamonga, CA) for performing ab-interno goniotomy.

METHODS

- Charts of all patients who underwent ab-interno goniotomy using the KDB device combined with phacoemulsification and/or endoscopic cyclophotocoagulation (ECP) at The University of Colorado Hospital Eye Center between October 1, 2014 and October 1, 2015 were reviewed retrospectively.
- Primary outcome measures included intra-operative and post-operative complications, IOP, and number of glaucoma medications.

RESULTS

- 21 eyes of 18 patients were reviewed
- One patient was excluded due to insufficient follow up
- The KDB procedure was successfully completed in all patients

Table 1:
Demographic characteristics of included patients

Demographics	
Sex	
Male	6
Female	11
Age	
Mean	69.5
Range	51-82
Laterality	
Right	8
Left	12
Type of Glaucoma	
POAG	12
CACG	3
PXG	3
PDG	1
Angle Recession	1
Prior Glaucoma Surgery	
SLT	5
Trabeculectomy	3
ExPress Shunt	1

Figure 1:
H&E stain of excised trabecular meshwork strip

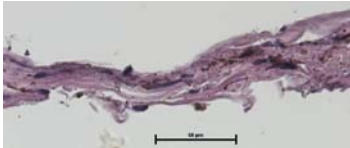


Figure 2:
Gonioscopic photo of the anterior wall of the canal of Schlemm after a KDB procedure



Table 2: IOP and medication use of included patients*

	Preop	POM1	POM3	POM6	Last Follow-Up
IOP	18.1±5.5mmHg	14.0±3.4 mmHg (p=0.003)	13.1±2.9 mmHg (p=0.009)	12.3±2.6 mmHg (p<0.001)	12.7±2.6 mmHg (p<0.001)
Medications	2.2±1.1	2.0±1.3 (p=0.470)	1.4±1.3 (p=0.094)	1.7±1.4 (p=0.569)	1.8 ± 1.4 (p=0.189)
n	20	20	12	7	20

*Continuous variables reported as mean ± standard deviation. p-values calculated using two-tailed paired student's t-test

Surgical Details

- 13 eyes were treated with combined phacoemulsification, endoscopic cyclophotocoagulation and KDB
- 4 eyes were treated with combined phacoemulsification and KDB
- 3 eyes were treated with combined endoscopic cyclophotocoagulation and KDB
- Mean follow up time was 4.3 ± 3.4 months (range 1-16)

Surgical Complications

- Intraoperative hyphema was observed in all eyes
- Post-operative hyphema was observed in 4 eyes and resolved by post-operative week 1 in all but 1 eye
- Inflammatory fibrin was observed in the anterior chamber in 2 eyes and resolved by post-operative week 1 in both eyes
- IOP spike at post-operative week 1 greater than 5mmHg above pre-operative IOP was observed in 4 eyes
- One patient required additional glaucoma surgery 2 months post-operatively for uncontrolled IOP

CONCLUSIONS

- In this short term study, the KDB device appears to be a safe and effective procedure for lowering IOP
- Further study is required to determine the long term safety and efficacy of this procedure

DISCLOSURES

Dr. Kahook is the inventor and holds patent rights to the KDB device. Dr. Seibold is a consultant to New World Medical. Drs. Kennedy and Soohoo report no relevant financial interests.

CONTACT INFO

jeffrey.kennedy@ucdenver.edu.

REFERENCES

- Seibold LK1, Soohoo JR, Ammar DA, Kahook MY. Preclinical investigation of ab-interno trabeculectomy using a novel dual-blade device. Am J Ophthalmol. 2013 Mar;155(3):524-529
- Jea SY, Francis BA, Vakili G, Filippopoulos T, Rhee DJ. Ab interno trabeculectomy versus trabeculectomy for open-angle glaucoma. Ophthalmology. 2012 Jan;119(1):36-42.
- Grover DS, Godfrey DG, Smith O, Feuer WJ, Montes de Oca I, Fellman RL. Gonioscopy-assisted transluminal trabeculectomy, ab interno trabeculectomy: technique report and preliminary results. Ophthalmology. 2014 Apr;121(4):855-61
- Khan M, Saheb H, Neelakantan A, Fellman R, Vest Z, Harasymowycz P, Ahmed II. Efficacy and safety of combined cataract surgery with 2 trabecular microbypass stents versus ab interno trabeculectomy. J Cataract Refract Surg. 2015 Aug;41(8):1716-24. doi: 10.1016/j.jcrs.2014.12.061.

Device Design

